

In the name of God

Case Study

Immobilized 78 y/o man with LBP
from 2 month ago

Sign and symptoms

- BW: 69
- Height: 170
- BT: 37
- BP: 140/85
- Low Back Pain VAS : 8
- Unable to standing up and walking

Physical Exam

- SLR 45+
- Force: 2/5R - 3/5L
- DTR: ↓
- Faber –
- Gaenselen –
- Painful pressure on lumbar vertebra

Differential Diagnosis

1. ?

2. ?

3. ?

4. ?

5. ?

6. ?

7. ?

8. ?

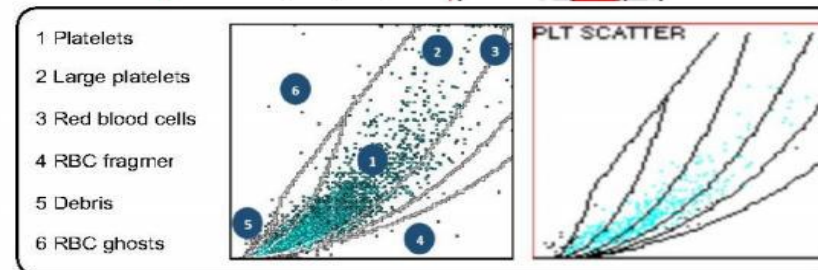
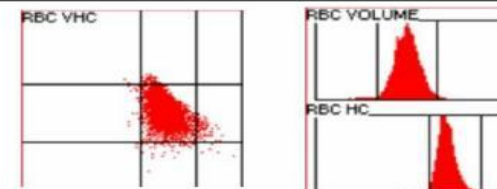
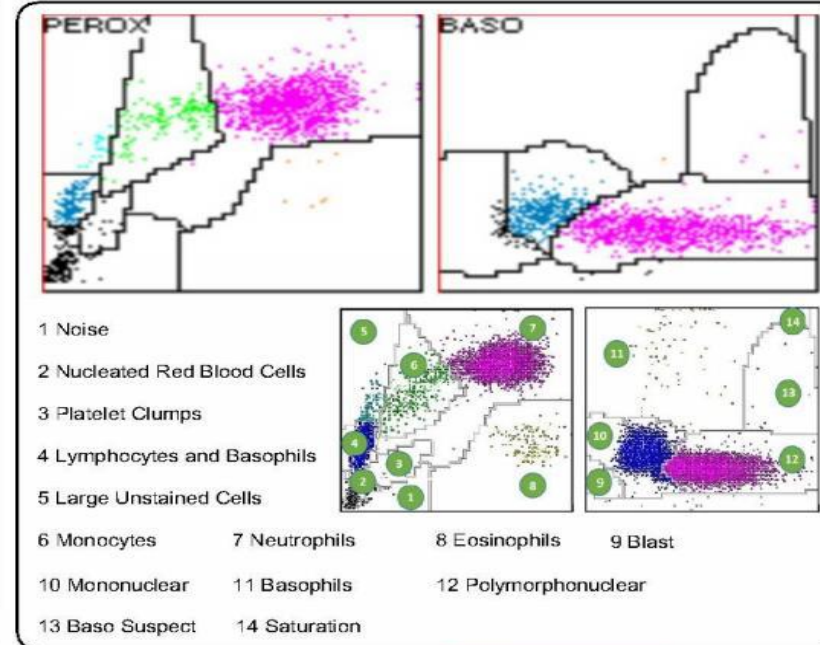
Laboratory tests:

CBC

TEST	RESULT	ABN	NORMALS	UNIT
WBC	10.02		(4.0 - 11.0)	10e3/ μ L
RBC	4.44		(4.1 - 6.1)	10e6/ μ L
HGB	13.2		(12 - 18)	g/dL
HCT	40.3		(37 - 54)	%
MCV	90.9		(80 - 99)	fL
MCH	29.8		(26.4 - 32)	pg
MCHC	32.8		(31 - 37)	g/dL
CHCM	32.7		(31 - 37)	g/dL
RDW	12.7		(11.5 - 16)	%
HDW	2.26		(2.0 - 3.2)	g/dL
PLT	187		(130 - 440)	10e3/ μ L
MPV	8.5		(6.1 - 11.1)	fL

WBC Diff

	%		10e3/ μ L	
NEUT	80.2	<10 Years (25-55) >10 Years (37-65)	8.04	(1.8 - 7.7)
LYMPH	13.4	<10 Years (30-65) >10 Years (25-40)	1.34	(1.0 - 4.8)
MONO	5.2	(3.4 - 9)	0.53	(0.16 - 1)
EOS	0.6	(0 - 7)	0.06	(0 - 0.45)
BASO	0.1	(0 - 5)	0.01	(0 - 1)
LUC	0.6	(0 - 4)	0.06	(0 - 0.4)
NRBC	0	(0.0 - 2.0)	0	(0.0 - 0.20)



Laboratory tests:

Hematology

Test	Risk	Result	Unit	Method	Normal Ranges
Bleeding time		1.30	min:sec	Manual	1 - 6
Clotting time		5	min:sec	Manual	2 - 6
PTT		30	Sec		25 - 45
<u>PT</u>					
PT		120	Sec		PT Control + - 2 sec
PT-Control		120	Sec		
Pt-Activity		100	%		70 - 100
INR		1.0			Standard dose therapy : 2 - 3 High risk patients : 2.5 - 3.5 Patients with LAs: 3 - 3.5

CBC

Attached Sheet

PCR با جوابدهي 2ساعته انجام مي شود.

در اين مرکز آزمايش ABL-BCR

Hormon

Test	Risk	Result	Unit	Method	Normal Ranges
Ferritin	H	408.87	ng/mL	CMIA	Males: 21-274

آزمایش Renin Activity در آزمایشگاه سلام راه اندازي شد

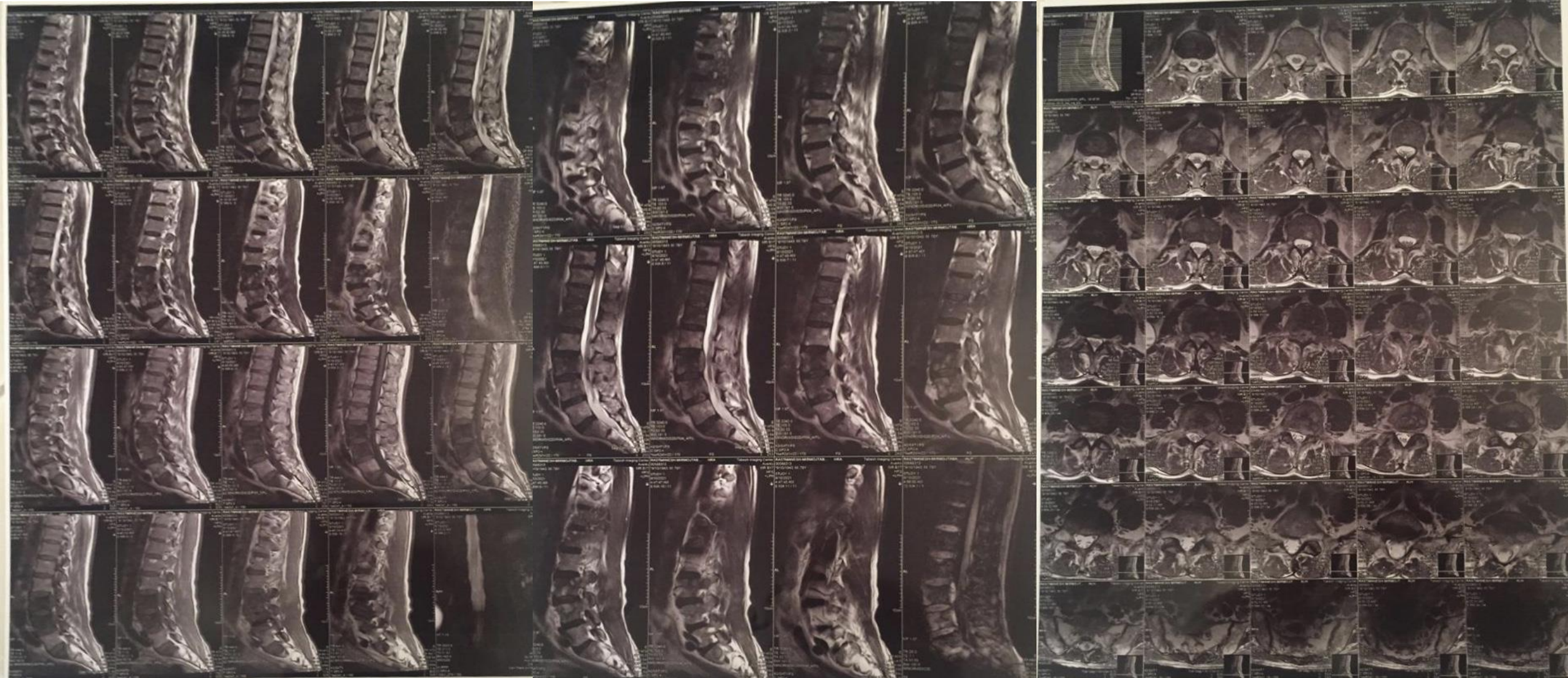Tumor Marker

Test	Risk	Result	Unit	Method	Normal Ranges
CEA	H	14.95	ng/mL	CMIA	Non smoker : Up to 5 In smoker : Up to 10
PSA(Total)	H	> 100.000	ng/mL	ECL	>=70Y: Up to 4.4
Free PSA	H	15.965	ng/mL	ELCIA	Up to 0.42

Biochemistry

Test	Risk	Result	Unit	Method	Normal Ranges
Iron Binding Capacity		308	mg/dL		250-450
Calcium		8.8	mg/dl		61-90 years: 8.8-10.2
Magnesium		2.5	mg/dl	Photo	male 13-150years : 1.8-2.6
Zinc		73	g/dL		Men : 72.6-127

MRI :



PET:

Last Name: RastManesh	First Name: MirMojtaba	Patient ID: 1460668855
Gender: Male	Study Date: 1400/06/29 (2021-09-20)	DOB: 1322 (1944)
		Patient's Tel: 09149721964

Diagnosis: Unknown Primary Cancer	Aim of Study: Diagnostic Evaluation	
BS at FDG injection: 113 mg/dL	Weight: 60 kg	Injected Activity: 343.4 MBq (9.28 mCi)
Inj. Site: Left Upper Extremity	Uptake Time: 69 min	Referring Physician: Dr. EgdamZamiri

History and Clinical Data:

The patient was referred for FDG PET-CT imaging study with a skeletal findings suspicious for metastases; and raised PSA (>150) and tumor marker (CEA).

Technic:

Standard whole body (skull base - mid-thigh) scan was performed in the arms-up supine position after intravenous injection of ¹⁸F-fluorodeoxyglucose (FDG) and waiting for the uptake time period. Imaging was performed with Siemens Biograph Horizon integrated PET-CT scanner. Computed tomography component of the study was performed with low dose protocol and without using oral or intravenous contrast materials; only for attenuation correction and anatomic localization purposes and cannot be used as diagnostic CT. Images were reviewed and interpreted. Pictures of important findings were printed and included.

Findings:

► Head & Neck Areas:

Mild and focal mucosal thickening is noted in right maxillary sinus without any FDG uptake.

Normal physiologic FDG uptake is seen in the major salivary glands, tonsils and nasopharyngeal areas.

There is not any obviously abnormal lymph node regarding size or FDG uptake in bilateral cervical lymphatic levels and supra/infraclavicular areas.

No obvious mass, nodule or focal FDG uptake is seen in bilateral lobes of the thyroid gland.

► Thorax, Lungs & Mediastinum:

There is no obvious nodule, mass lesion or significant abnormal FDG uptake within lungs.

Many millimetric hyperdense nodules are seen in the bilateral lungs, compatible with cement embolization secondary to recent cement vertebroplasty.

In the mediastinum, no abnormally large or hypermetabolic lymphadenopathy is detected except for one subcentimetric lymph nodes without significant FDG uptake at precarinal area.

Focal pleural thickening is noted adjacent to lytic/destructive metastatic lesion of anterolateral portion of left 2nd rib.

► Abdomen & Pelvis:

There is not any obvious mass lesion or abnormal FDG uptake in the liver and spleen.

No obvious mass lesion or abnormally increased FDG uptake is noted at adrenal glands.

There are is a 72 × 61 × 45 mm cystic lesion at inferior pole of right kidney.

One focus of mild FDG uptake (SUVmax= 4.31) is seen at left lateral zone of prostate gland.

There is not any other notable mass, prominent lymphadenopathy, free fluid or obviously abnormal FDG uptake in the abdominal and pelvic cavities.

Prevalence

- 50% of all adults have low back pain every year
- 15 – 20% seek medical attention
- 70 % IMPROVE WITHIN 2 WEEKS
- 90 % IMPROVE WITHIN 6 WEEKS
- 3% DO NOT IMPROVE WITHIN 6-12 WEEKS
- 50 % of low back pain (LBP) cost is due to these patients

Who Treats The Pain

- Family physicians and internists
- **Physiatrists**
- Chiropractors
- **Neurologists**
- Pain specialists and anesthesiologists
- Pain psychologists
- **Spine surgeons**

Causes Of Pain in Lower Back & Extremities

- Sprained/strained ligaments, tendons, muscles • Herniated discs
 - Spinal Stenosis
 - Degenerative disc disease
 - Spondylolysis, Spondylolisthesis • Facets joints arthritis
 - Sacroiliac joint
 - Osteoporosis
 - Ankylosing Spondylitis
 - Arthritis (osteoarthritis and rheumatoid arthritis)
-

Causes Of Pain in Lower Back & Extremities

- Deformities (Kyphosis, Lordosis, Scoliosis)
- Fibromyalgia, myofascial pain
- Emotional stress
- Vertebral body fractures
- Infection (osteomyelitis, abscess, archedoditis) • Osteomalacia
- Cancer
- Referred pain
- Reflex sympathetic dystrophy (RSD)

Radiating Low Back Pain

- Disc Herniation
 - Nerve Impingement
 - Spinal Stenosis
 - Sacroiliac joint dysfunction
 - Myofascial Pain
 - Cancer
 - Infection
-
-

Non-Radiating Low Back Pain Causes

- BACK STRAIN-Muscles • Osteoarthritis of spine
 - Cancer
 - Fracture
 - Osteoporosis
 - Spondylolisthesis
 - Spondylolysis
 - Ankylosing spondylitis
-

Spinal Canal Stenosis

- Greater than 50 years of age (usually in 60's or 70's)
- LBP and leg pain with walking
- Neurologic Claudication
- Can be unilateral or bilateral
- Increased pain with down hill walking and better with walking uphill
- + “shopping cart” sign

Red flags: Summary (Mnemonic: TUNA FISH, as an aid to documentation)

T - Trauma

U - Unexplained Weight Loss

N - Neurologic findings (includes bowel or bladder Incontinence and other Cauda Equina Syndrome symptoms)

A - Age >55 years (or age >65 years)

F - Fever

I - Immunocompromised

S - Steroids

H - History of HIV, Tuberculosis, Cancer

Cancer Related Red Flags with Low Back Pain

- History of cancer
- Unexplained Weight Loss >10 kg within 6 months
- Age over 50 years or under 18 years old
- Failure to improve with therapy
- Pain persists for more than 4 to 6 weeks
- Night pain or pain at rest

Infection Related Red Flags with Low Back Pain

- Persistent fever (Temperature over 100.4 F)
- Poor Test Sensitivity for Spinal Infection
- History of Intravenous Drug Abuse
- Severe Pain
- Lumbar Spine surgery within the last year
- Recent Bacterial Infection
- Urinary Tract Infection or Pyelonephritis
- Cellulitis
- Pneumonia
- Wound (e.g. Decubitus Ulcer) in spine region
- Immunocompromised states
- Systemic Corticosteroids
- Organ transplant
- Diabetes Mellitus
- Human Immunodeficiency Virus (HIV)
- Rest Pain

Cauda Equina Syndrome Related Red Flags with Back Pain

- Urinary Incontinence or retention
- Saddle Anesthesia
- Anal sphincter tone decreased or Fecal Incontinence
- Bilateral lower extremity weakness or numbness
- Progressive neurologic deficit
- Major motor weakness
- Major sensory deficit

Significant Herniated nucleus pulposus

- Major Muscle Weakness (strength 3 of 5 or less)
- Foot drop

Vertebral Fracture related red flags with Low Back Pain

- Prolonged use of Corticosteroids
- Age greater than 70 years
- History of Osteoporosis
- Mild Trauma over age 50 years (or with Osteoporosis)
- Recent significant Trauma at any age
- Ejection from motor vehicle
- Fall from substantial height

Abdominal Aortic Aneurysm red flags with Low Back Pain

- Abdominal pulsating mass
- Atherosclerotic vascular disease
- Pain at rest or nocturnal pain
- Age greater than 60 years

Red Flags: General (weak Test Specificity)

- Vertebral tenderness
- Limited spine range of motion

WHAT? WHY? HOW? WHERE? WHEN? WHO? WHICH? WHOSE?

WHERE? HOW? WHO? WHAT? HOW?